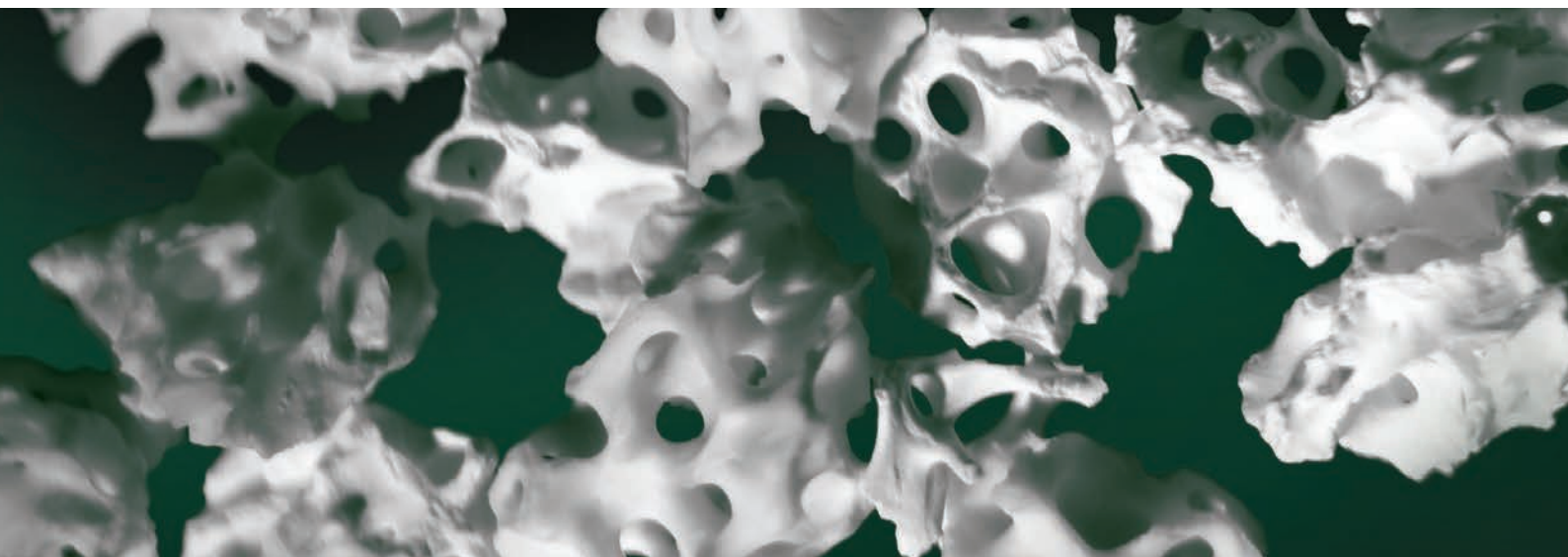

# Ti-oss<sup>®</sup> resorption by Osteoclast found on 8 weeks rat model.

Korea University Hospital, Dental Division, Oral and maxillofacial department

Jun, Sangho, DDS, MS, Ph.D

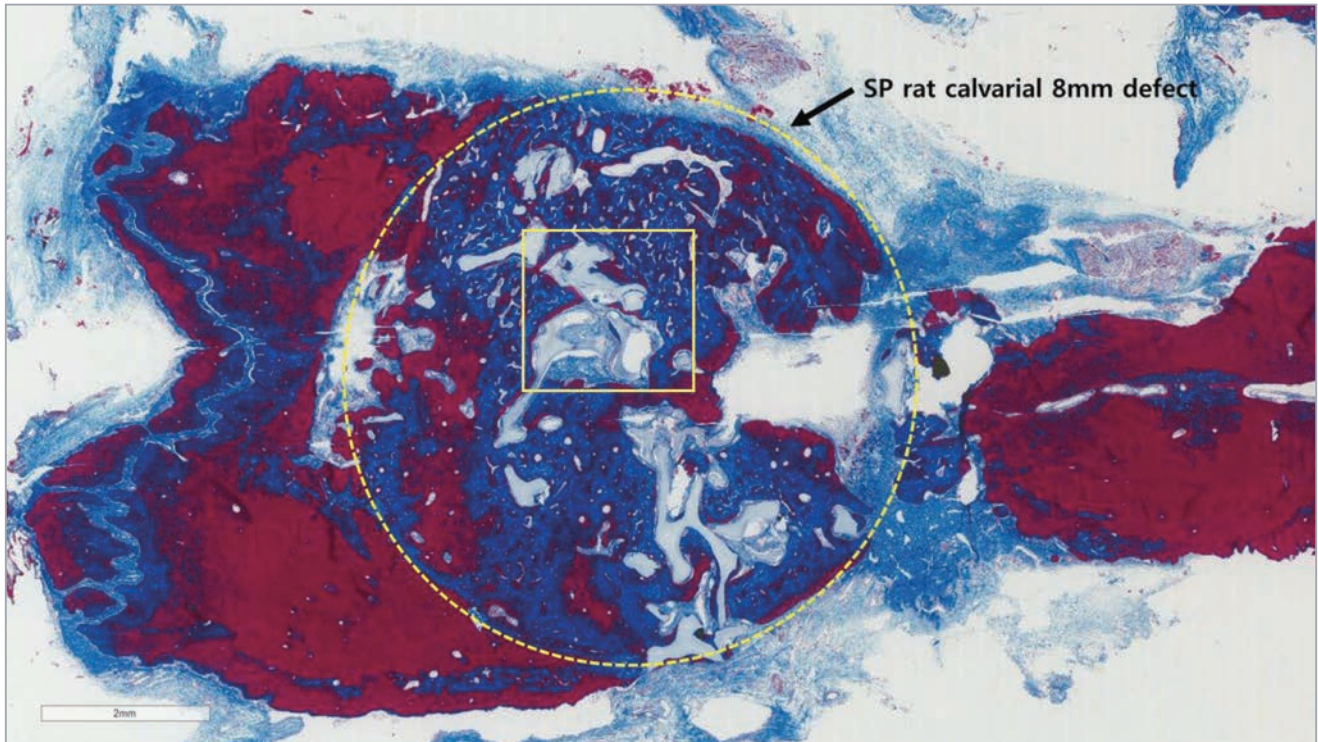
Korea University Hospital, Dental Division, Prosthodontic department

Ryu, Jaejun, DDS, MS, Ph.D

May, 2015

# Ti-oss<sup>®</sup> resorption by Osteoclast found on 8 weeks rat model.

In 8 weeks after the placement of Ti-oss<sup>®</sup> bone graft, rat calvarial defect has been filled into the defect center.



Ti-oss<sup>®</sup> resorption by Osteoclast was found at 8 weeks after the placement of Ti-oss<sup>®</sup> graft onto the surgical defect. (yellow square)

